

## LETTER TO THE EDITOR

### Comparison of three different needles for percutaneous injections

Several percutaneous local ablative therapies have been used to treat unresectable malignancies including percutaneous ethanol injection therapy (PEIT), acetic acid, hyperthermic saline and distilled water, gene therapy, liposomal or micelle vectors, and chemotherapeutic agents such as cisplatin. However, mechanical methods for injection of therapeutics remain primitive. Treatments must be able to distribute a small volume of therapeutic agent evenly and widely throughout the tumor, including the tumor margin, without tracking along fascial planes and killing healthy tissue.

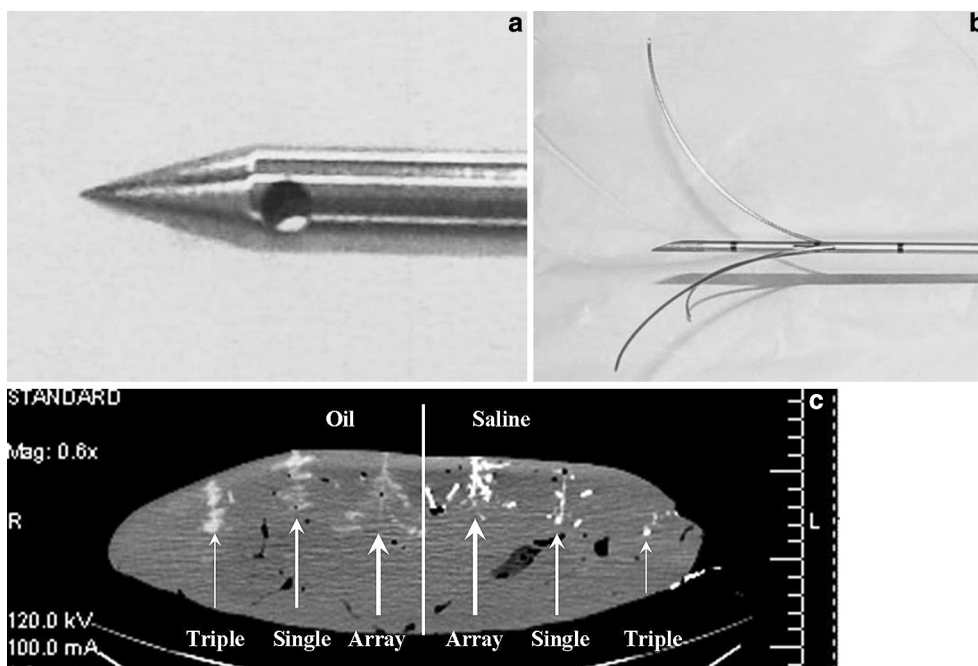
Because percutaneous injection therapy relies on the ability to accurately distribute the therapeutic agent within the tumor, the orientation of the needle and needle holes may be an important factor. Two different types of needles are commonly used in percutaneous injection procedures: single end-hole needles and needles with a closed conical tip and three terminal side-holes (Fig. 1A). Alternatively, a three-pronged array needle with variable intra-prong distances (Fig. 1B) has recently become available (Quadra-Fuse, Rex Medical, Radnor, PA, USA). The injection distributions of these three injection systems were compared.

For this purpose, an experiment was performed on a 7.71 kg cow liver comparing three distinct types of injection needles: an 18G, 15 cm DISP Chiba Biopsy needle with a single end-hole (Cook, Bloomington, IN, USA); a 22G, 15 cm Bernadino three side-hole infusion needle (Cook, Bloomington, IN, USA); and an 18G Rex Medical Quadra-Fuse three-pronged array injection

needle (Rex Medical, Radnor, PA, USA). Each needle type (single end-hole, three side-hole, and array) was used to inject two different contrast solutions (5 cm<sup>3</sup>). All six injections were in the same plane to ensure visualization in one computed tomography (CT) slice (Fig. 1C). The two different contrast solutions used to visualize injection were 10% Hypaque-Cysto (diatrizoate meglumine) in normal saline, and 10% ethiodol (37% iodine) in Johnson's Baby Oil (Johnson & Johnson, Skillman, NJ, USA).

For the single end-hole and three side-hole needles, contrast solution was injected beginning at 3 cm with the tips slowly raised in approximately 2 mm increments with 0.5 cm<sup>3</sup> injections until 4 cm<sup>3</sup> had been injected. The needles were then lowered to the initial 3 cm depth and the remaining 1 cm<sup>3</sup> was injected. The array needle was inserted 3 cm into the liver and deployed 1 cm. Then 0.5 cm<sup>3</sup> of contrast solution was injected. The array was retracted, the needle rotated 60° and redeployed to 1 cm followed by another 0.5 cm<sup>3</sup> injection. This method was repeated with deployment increments of 1 cm until the entire 5 cm<sup>3</sup> volume was injected (5 cm maximum deployment). A detailed image analysis of the solutions' trajectories within the cow liver was done with a helical CT scanner (General Electric, 120 kV, 100 mA, 0.625 mm slice thickness, 0.625 cycles per second).

The three side-hole needle provided improved echogenicity and linear tracking compared with standard biopsy needles. Using equivalent injection volumes, the three side-hole needle produced greater zones of chemical dispersion for both the saline and oil contrast agents when compared with the single side-hole needle. Both the single-side-hole and the three side-hole needles produced confined distributions. A study by Geschwind et al.



**Fig. 1.** a-c. Diffusion of contrast agent by single end-hole, three side-hole, and array needles. **a** Three side-hole needle. **b** Array needle. **c** Coronal CT scan of cow liver showing distribution of contrast agent by type of needle.

compared necrosis diameters and volumes after PEIT using a single side-hole needle and the three-pronged array needle. After injection of identical volumes of ethanol, the three-pronged array needle achieved larger necrosis volumes and diameters [1].

Contrast injection was better distributed and dispersed over a broader volume with the array needle (Fig. 1B) compared with the same contrast volume with the other needles. Both the single end-hole needle and to a lesser extent the three side-hole needle (Fig. 1A) produced poorly controlled injection distributions. These distributions appeared to be elongated in the anterior-posterior plane parallel to the direction of the needle, presumably along blood vessels and fascial planes. The array needle produced a star-shaped distribution visualized regularly in coronal slices (Fig. 1C). After allowing sufficient time for diffusion, a spherical zone of contrast agent was visualized around the array, while the distributions around the single end-hole and three side-hole needles were elongated and less uniform. Although measurements were done retrospectively in the *x*-axis using one CT image, the array needle had a 5.0 cm zone of distribution with both oil and saline. The single end-hole needle had a 2.0 and 2.5 cm zone of distribution for oil and saline respectively. The triple side-hole needle had a zone of distribution of 2.0 and 1.0 cm for oil and saline, respectively.

While these findings are intriguing, there are several limitations to this study. Because the experiment was performed *ex vivo*, the lack of perfusion may have limited the distribution of contrast solution. However, this limitation is likely to affect all three needles similarly. Because the liver specimen was not uniform and injections were performed only once with each contrast solution, variable orientations of fascial planes and vasculature might have affected the distributions of each needle unequally. Confirming these distribution patterns *in vivo* and correlating these observations with the imaging and histologic findings might verify our findings. Moreover, depending on the disease process affecting the liver (i.e., primary hepatocellular carcinoma versus metastatic liver disease versus cholangiocarcinoma), diffusion of contrast agents

may differ and subsequently CT imaging of contrast distribution may not correlate with cell destruction. While these limitations preclude a quantitative analysis of volume distributions within the liver specimen, the qualitative results obtained from CT are still interesting.

Qualitative visualization of injection distributions suggests that the array needle might produce more spherical distributions which would presumably lead to more predictable zones of treatment. The array needle is currently our needle of choice for injectable therapeutics and is being used to inject gene therapy in a clinical trial. More uniform distribution of injected anticancer agents could improve efficacy of current percutaneous therapies.

*Deepak Sudheendra*

*Rosanne Léger*

*Eli R. Groppo*

*David Sun*

*Amir K. Durrani*

*Ziv Neeman*

*Bradford J. Wood*

Department of Radiology, Warren G. Magnuson Clinical Center  
National Institutes of Health, Building 10, Room 1C-660  
Bethesda, MD, 20892, USA  
*email: sudheendrad@cc.nih.gov*

*Acknowledgment.* This research was supported in part by the Intramural Research Program of the NIH, Clinical Center.

## Reference

1. Geschwind J, Kobeiter H, McGee C (2006) Chemical ablation of liver tissue with a new injection device: Preliminary results and assessment of necrosis in normal pigs. Available at <http://www.rexmedical.com/HopkinsanimalstudyFINAL91902.htm>. Accessed on March 27, 2006